
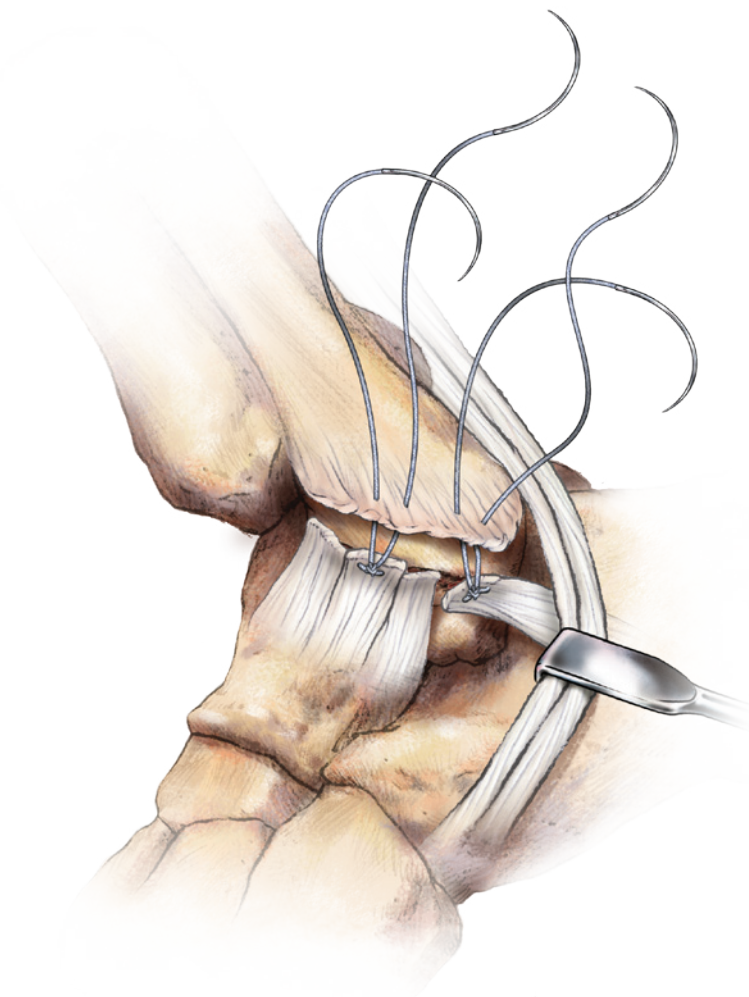


JuggerKnot™
SOFT ANCHOR



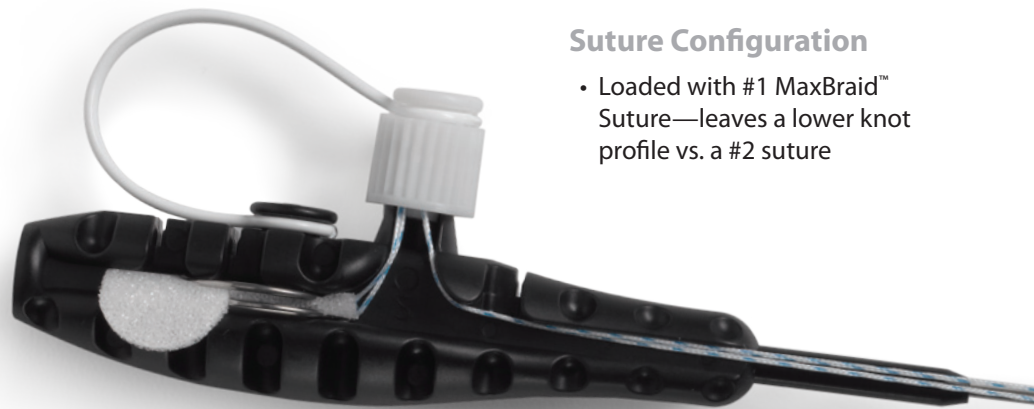
Lateral Ankle Ligamentous Instability

Surgical Protocol by
Jeffrey Nacht, M.D.

BIOMET®
SPORTS MEDICINE

It's small. It's strong. And it's all suture.

The **JuggerKnot™ Soft Anchor** represents the next generation of suture anchor technology. The 1.4mm deployable anchor design is a completely **suture-based** system, and is the **first of its kind**.



Suture Configuration

- Loaded with #1 MaxBraid™ Suture—leaves a lower knot profile vs. a #2 suture

Needles


- Tapered #5 needles can be used to tie down ligaments



This brochure is presented to demonstrate the surgical technique and postoperative protocol utilized by Jeffrey Nacht, M.D. Biomet Sports Medicine, as the manufacturer of this device, does not practice medicine and does not recommend this or any other surgical technique for use on a specific patient.

JuggerKnot™

SOFT ANCHOR

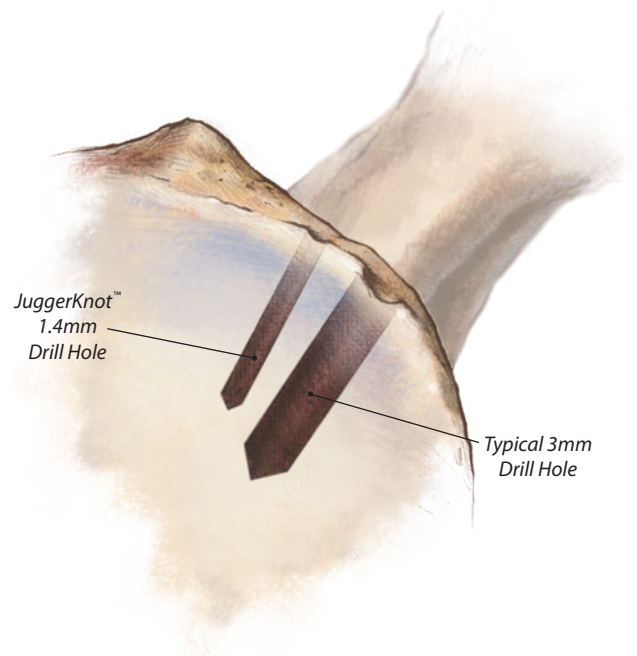


Minimal Size

- Smaller drill guide is less invasive to surrounding tissue
- Smaller anchor diameter allows multiple anchors to be placed
- Reduces likelihood of intersecting anchors when placing multiple anchors

Soft Material

- Soft anchor deployment system—completely suture based implant
- Implant made from #5 polyester suture
- Eliminates the possibility of rigid material loose bodies in the joint



Reduced Bone Removal

- The volume of bone that is removed with a 3.0mm drill is equivalent to four JuggerKnot™ device drill holes



Surgical Technique

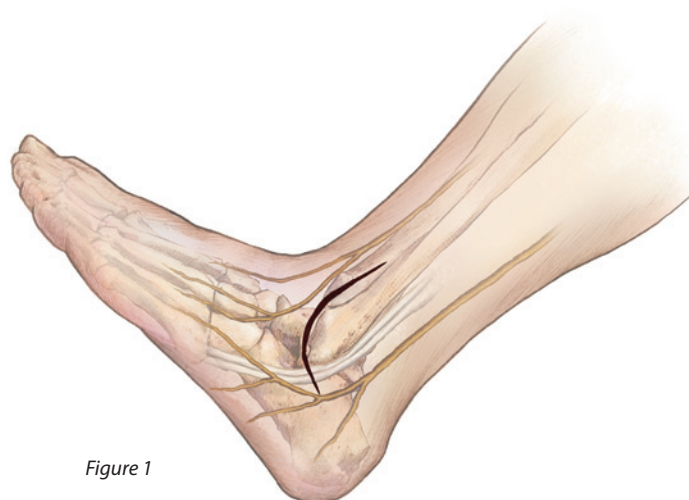


Figure 1

Introduction

Several procedures have been described using the Biomet Sports Medicine JuggerKnot™ Soft Anchor, designed to take full advantage of its ease of use, rapid deployment, small footprint within the bone, and its ability to provide fixation in multiple layers which can save time and decrease the need for surgical exposure and dissection compared with standard techniques.

Pre-Operative Preparation and Positioning

A popliteal block is placed for postoperative analgesia before beginning the procedure. The patient is then anesthetized with regional or general technique and placed in a full lateral or semi-lateral position (surgeon's preference) and secured with a vac-pack or similar device.

A semi-lateral position is preferred to allow the addition of a diagnostic ankle arthroscopic procedure, which is included with most cases, due to the high incidence of accompanying intra-articular pathology.

A tourniquet may be placed at either the mid-calf or the mid-thigh. Generally, the mid-thigh is preferred so that the surgeon may choose to augment the repair with a local transfer of a peroneal tendon if the local tissues are found to be inadequate to accomplish the procedure. A small roll of sterile towel is placed beneath the ankle to support the inverted ankle position during the procedure.

Incision

The incision is placed as a gently curving line running approximately 1 cm anterior to the distal fibula and following its line inferiorly toward the peroneal tendons (Figure 1). Alternatively, a posteriorly placed curving incision along the posterior edge of the fibula and then curving onto the lateral border of the foot can also be used. This allows easier access to the peroneal tendons. The skin and subcutaneous tissue is divided and retracted with skin hooks or senn rakes.

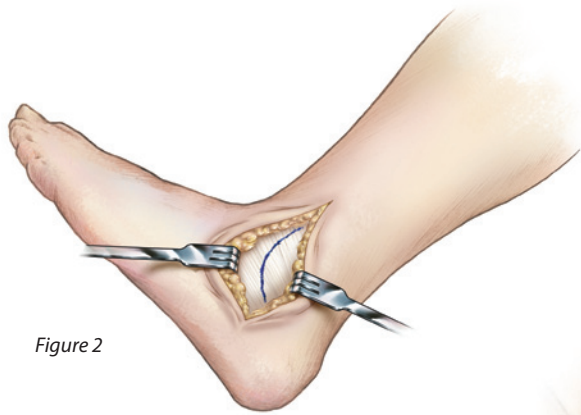


Figure 2

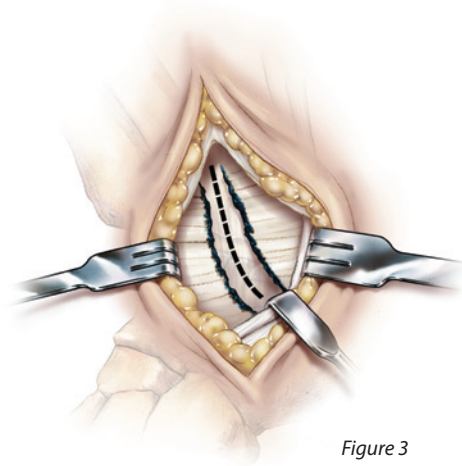


Figure 3

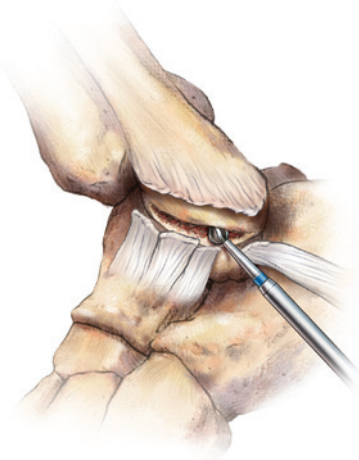


Figure 4

Dissection

Next the inferior extensor retinaculum is dissected from the subcutaneous layer distally and slightly proximally, to prepare for later reefing. A marking pen can be used at the incision in the retinaculum to aid in finding this edge for later closure (Figure 2). After incising this layer along the marked line, it is retracted to expose the ankle capsule.

Tip: To ensure that the ankle is opened and the subtalar joint is not inadvertently violated, palpate the edge of the fibular malleolus and the ankle joint with a 22 gauge needle before making an incision.

The capsule is then incised along the anterior edge of the fibula, following the bone edge inferiorly. Before reaching the peroneal tendons, insert the blunt end of a senn rake or ragnel retractor to protect the peroneals as the incision is carried posteriorly. This step also exposes the Calcaneofibular ligament (CFL) which lies just beneath the peroneal tendons in this location and is easily located by "toeing-in" the senn rake (Figure 3).

The CFL is released off the fibula and the ankle is inspected for any loose bodies and debris .

By sharp dissection, the fibular periosteum is elevated off the edge of the fibula and carefully preserved for later use in the repair. The distal and anterior edge of the fibula is prepared with a 3–4 mm burr, creating a shallow decorticated trough into which the ligaments will be re-attached (Figure 4).

Surgical Technique

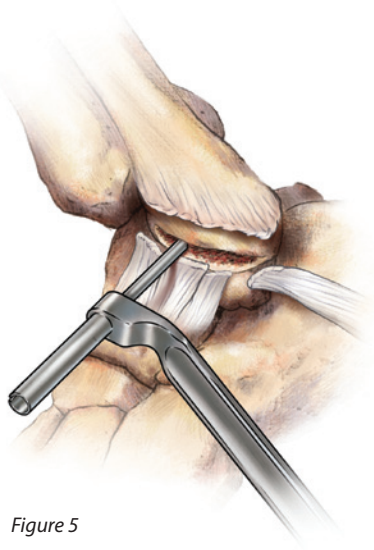


Figure 5

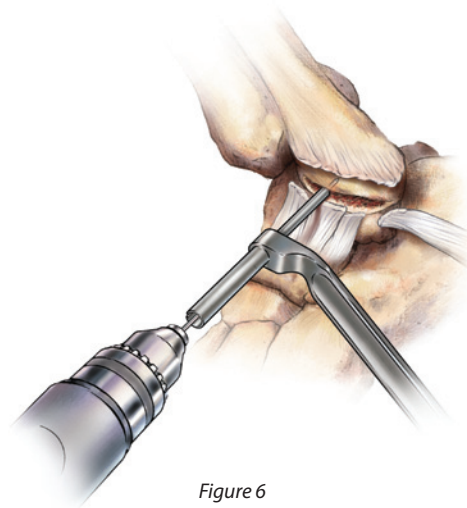


Figure 6

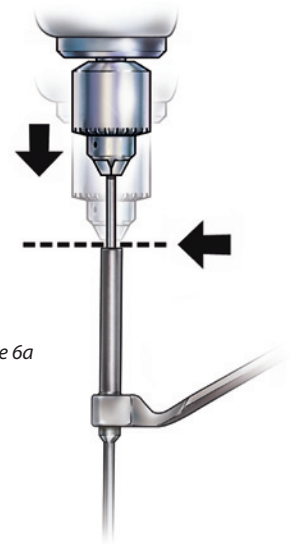


Figure 6a

Placement of the JuggerKnot™ Short Guide

Next, place two JuggerKnot™ Soft Anchors. The first anchor should be placed onto the fibula where the anterior talo-fibular ligament (ATFL) should be reattached. The second anchor should be placed at the inferior tip of the fibula where the Calcaneofibular ligament (CFL) will be re-attached. Start by placing the JuggerKnot™ guide onto the fibula where the ATFL should be reattached (Figure 5) .

Drill the Pilot Hole

Without moving the guide insert the JuggerKnot™ drill bit into the power drill to the proximal laser-etch line to ensure appropriate depth as the collar of the drill contacts the back of the guide. Advance the drill until contact is made with the guide (Figures 6 & 6a).

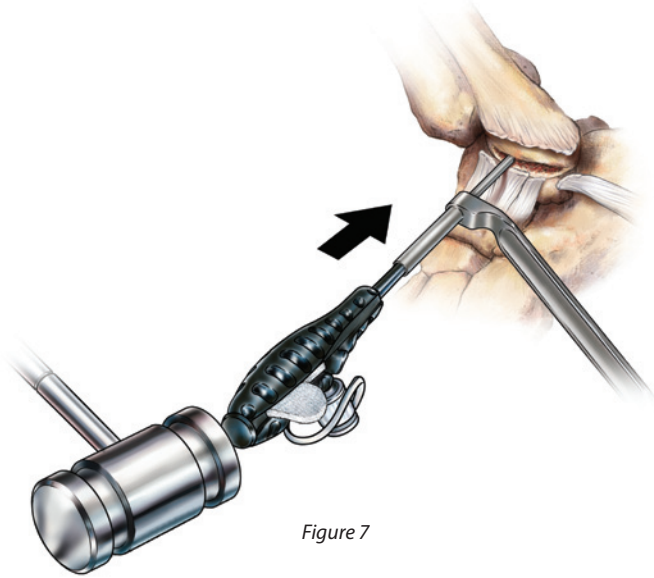


Figure 7

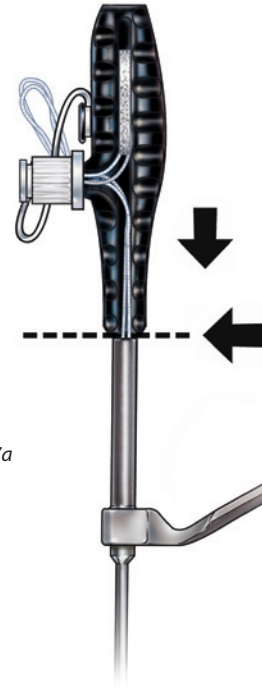
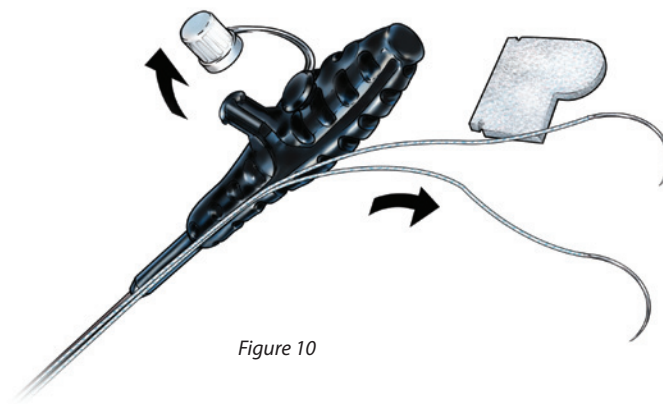
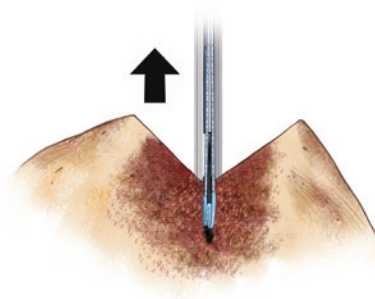
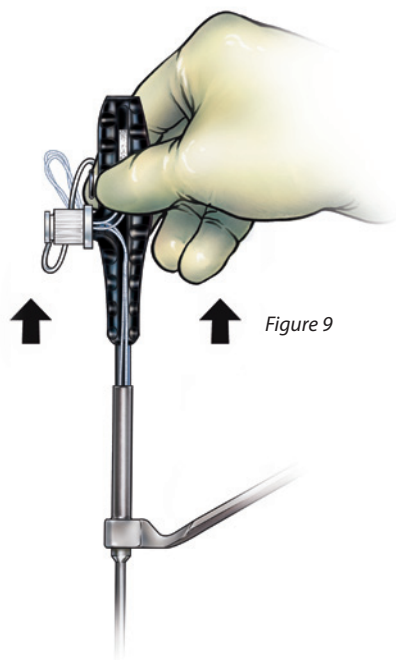


Figure 7a

Insert the Anchor

Remove the drill. **Note: Caution must be taken to maintain precise guide position over the pilot hole during removal.** While maintaining the guide position firmly against the bone, insert the JuggerKnot™ Soft Anchor through the guide and into the pilot hole. Lightly mallet to fully seat the anchor into bone (Figures 7 & 7a).

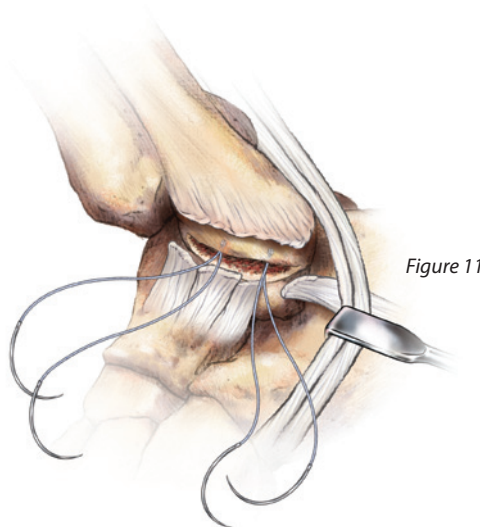
Surgical Technique



Deploy the Anchor

Once anchor has been fully seated into the fibula, lightly pull back on the anchor inserter handle to set the anchor (Figure 9). Release the suture from the handle by unscrewing suture retention feature and remove the needles from the middle of the guide (Figure 10). Pull the anchor inserter handle directly back from the guide. Lightly pull on both sutures to set the anchor and verify the sutures slide (Figure 9a).

Repeat these steps to place the second JuggerKnot™ Soft Anchor on the fibula at the location of the CFL (Figure 11).



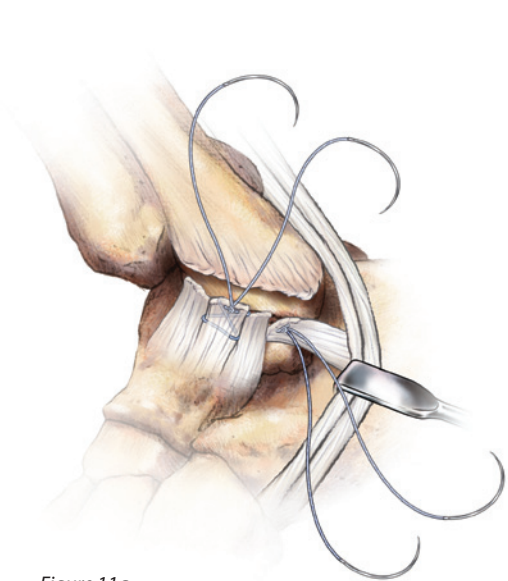


Figure 11a

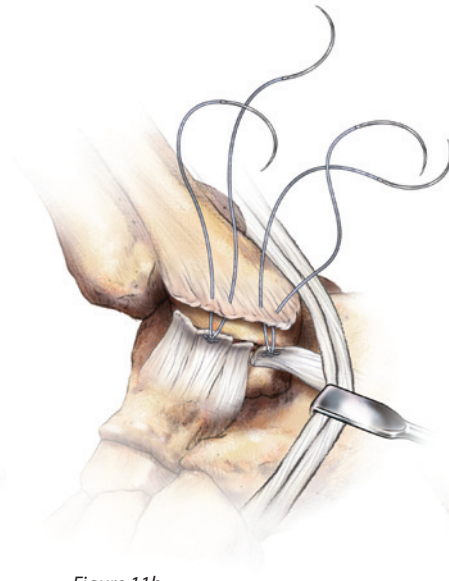


Figure 11b

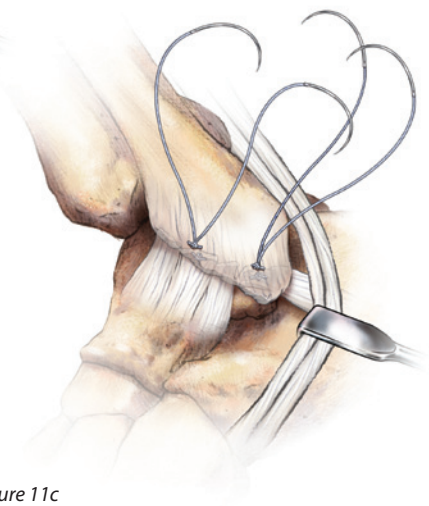


Figure 11c

Repair the Tendons

Use the needles attached to the Juggerknot™ Soft Anchor (#5 Taper Needle) to pass the Maxbraided™ sutures. The anterior sutures are passed in a modified Bunnell fashion through the thickened capsule at the site of the ATFL, passing the needle twice into the ligament for each suture limb. Next, the posterior sutures are passed into the edge of the CFL in a similar manner (Figure 11a). The towel roll is now removed from beneath the ankle and the foot placed

in a neutral position. While the assistant holds the ankle in a gently everted position, the sutures are tied, bringing the ligaments snugly up against the prepared bone edge at the proper tension. This completes the first layer of repair. The sutures are **NOT** cut.

The same sutures are then passed through the periosteal layer on the fibula and tied over this second layer, tucking it over the primary repair as reinforcement. **Again, the sutures are NOT cut.** (Figures 11b & 11c)

Surgical Technique

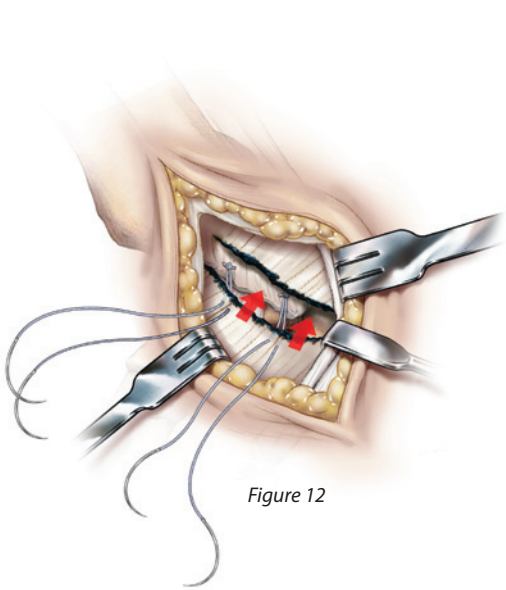


Figure 12

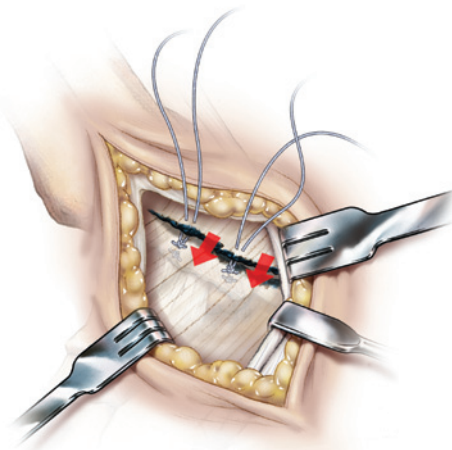


Figure 13

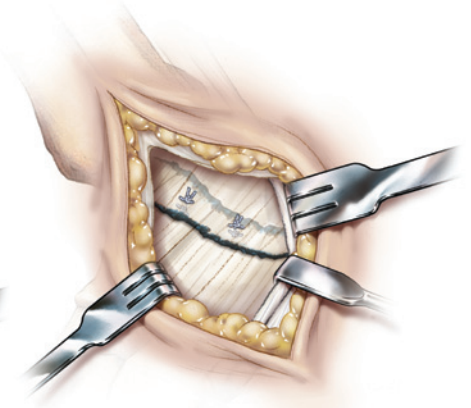


Figure 14

The distal edge of the Inferior Extensor Retinaculum is now pulled up over the repair and the sutures are passed through this layer and tied again, providing the "Gould" reinforcement (Figure 12). Finally, the proximal edge of the Inferior Extensor Retinaculum is drawn over top of the distal edge in a "pants-over-vest" manner to further reinforce the repair (Figure 13). The JuggerKnot™ sutures are cut after this last repair (Figure 14).

Testing the Repair

The repair is now evaluated by lifting the limb off the operating table. The ankle should now have enough lateral stability to resist inversion from the force gravity. Further, full ankle dorsiflexion and plantarflexion should be permitted to passive range of motion.

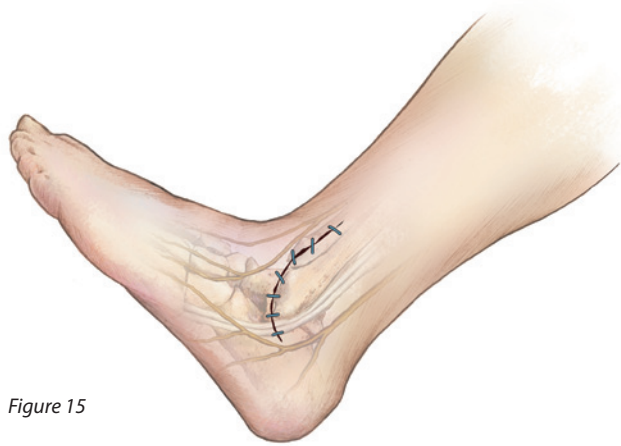

Figure 15

Closure

A running suture of 2-0 Vicryl or similar absorbable suture is then placed from anterior to posterior along the retinacular repair line. The subcutaneous and skin layers are re-approximated with the surgeon's preferred technique (Figure 15).

A well-padded posterior splint, with medial, lateral, and posterior plaster slabs secured with an elastic bandage, is prepared with an ABD pad over the heel. The ankle is held in a gently everted and dorsiflexed position as the splints sets up.

Ordering Information

JuggerKnot™ Soft Anchor Short w/Needles	
912068	1.4mm Single Loaded
912069	1.4mm (Package of 10)

JuggerKnot™ Soft Anchor Short 1.4mm Drill Bit (Disposable)

912071 Sterile

JuggerKnot™ Soft Anchor Short 1.4mm Guide (Reusable)

912072 Non-Sterile

All trademarks herein are the property of Biomet, Inc. or its subsidiaries unless otherwise indicated.

This material is intended for the sole use and benefit of the Biomet sales force and physicians. It is not to be redistributed, duplicated or disclosed without the express written consent of Biomet.

For product information, including indications, contraindications, warnings, precautions and potential adverse effects, see the package insert on Biomet's website.

BIOMET®
SPORTS MEDICINE
One Surgeon. One Patient.™

P.O. Box 587, Warsaw, IN 46581-0587 • 800.348.9500 ext. 1501
©2011 Sports Medicine • www.biometSPORTSMEDICINE.com
Form No. BSM0282.0 • REV123111

www.biometSPORTSMEDICINE.com